

See discussions, stats, and author profiles for this publication at: <https://www.researchgate.net/publication/329984563>

Small bowel adenocarcinoma in a patient with a 5-year history of untreated Crohn's disease: a case report

Article in *Il Giornale di Chirurgia - Journal of Surgery* · November 2018

CITATIONS

0

READS

98

6 authors, including:



Salvatore Fedele
Policlinico di Bari

20 PUBLICATIONS 87 CITATIONS

[SEE PROFILE](#)



Antonella Delvecchio
Ospedale Generale Regionale "F. Miulli"

50 PUBLICATIONS 390 CITATIONS

[SEE PROFILE](#)



Gennaro Martines
University of Bari Aldo Moro

124 PUBLICATIONS 1,513 CITATIONS

[SEE PROFILE](#)

Small bowel adenocarcinoma in a patient with a 5-year history of untreated Crohn's disease: a case report

S. FEDELE, A. DELVECCHIO, C. DE GIORGI, L. DUDA, A. GUGLIELMI, G. MARTINES

SUMMARY: Small bowel adenocarcinoma in a patient with a 5-year history of untreated Crohn's disease: a case report.

S. FEDELE, A. DELVECCHIO, C. DE GIORGI, L. DUDA, A. GUGLIELMI, G. MARTINES

Aim. Complication of Crohn's disease (CD) of the small intestine is small bowel adenocarcinoma (SBA). A lot of studies on Crohn's disease have estimated the increased relative risk of small bowel carcinoma compared to the general population. In clinical settings, it is difficult to detect SBA in CD, therefore most of cases are diagnosed after surgery for strictures without suspicion of malignancy.

Case report. The present case concerns a 48-year-old man with a suspicious 5-year history of untreated chronic inflammatory bowel disease. The patient was admitted to our unit with persistent abdominal

pain, 20 kg weight loss and intestinal obstruction, confirmed at CT scans. It was performed an emergency laparotomy, terminal ileus was resected and intestinal continuity was restored. Histological examination revealed a poorly differentiated adenocarcinoma.

Discussion. The risk factors of SBA include long-standing and extensive Crohn's disease, young age, male sex, smoke, early onset, complications such as strictures and fistulas. The most common clinical presentation of small bowel carcinoma in Crohn's disease is intestinal obstruction accompanied by weight loss. The diagnosis is very difficult because imaging techniques may not be able to differentiate areas of small bowel carcinomas from benign fibrotic or acute inflammatory strictures.

Conclusion. Small bowel adenocarcinoma is a rare disease but this evenience must be considered in patients with strictures for Crohn's disease. Preoperative diagnosis is still highly challenging despite significant radiological and endoscopic progress.

KEY WORDS: Crohn's disease - Small bowel adenocarcinoma - Intestinal obstruction

Introduction

An unquestionable complication of Crohn's disease (CD) of the small intestine is small bowel adenocarcinoma (SBA). It was reported for the first time by Ginzburg in 1956 (1) and since then numerous case reports have been published. The estimated number of annual new cases of SBA in Europe is 3600 (2) and the incidence rate is 5.7 cases per million persons. Several population-based studies on Crohn's disease have estimated the increased relative risk of small bowel carcinoma which ranges from 17 to 41 compared to the general population (3, 4). The risk is in-

creased in an inflamed small bowel segment, particularly in the ileus, and appears more frequently in younger patients as compared with *de novo* cancers. After 10 years of Crohn's medical history, there is a cumulative risk approximately of 0.2% which rises to 2.2% after 25 years (5). Some authors (6) suggest that small bowel resection and prolonged salicylates use may protect against small bowel cancer in CD patients. In clinical settings, it is difficult to detect SBA in CD, therefore most of cases are diagnosed after surgery for strictures without suspicion of malignancy. Here, we report a patient with a suspicious 5-year history of untreated chronic inflammatory bowel disease who developed a SBA that was detected by histology after emergency surgery for small bowel obstruction.

General Surgery Unit, "Azienda Ospedaliero Universitaria Policlinico Bari", Bari, Italy

Corresponding author: Gennaro Martines, e-mail: gerrymartines@virgilio.it

© Copyright 2018, CIC Edizioni Internazionali, Roma

Case report

A 48-years-old man with a 5-years-old referred intermittent medical history of diarrhea had several hospitalizations for malnutrition and temporary intestinal obstructions. Therefore, he underwent a MRI enterography and colonoscopy with ileal biopsy specimen which supported a suspected Crohn's disease. His family history was negative for this disease, he was a smoker and had no evidence of gluten intolerance. He was treated with 5-aminosalicylates combined with corticosteroids and azathioprine therapy and received also infliximab. For malnutrition, it was administered total parental nutrition.

After only three months of therapy, he was admitted to our unit with persistent abdominal pain, 20 kg weight loss and intestinal obstruction. Physical examination revealed a distended abdomen with hypoactive bowel sounds. The laboratory data were within normal limits, except for hypocalcaemia and hypoproteinaemia. Abdominal plain film x-rays showed small bowel obstruction (Figure 1) and CT showed dilatation of small bowel loops, wall thickening of terminal ileus and associated local lymphadenopathy as active Crohn's disease (Figure 2).

It was performed an emergency laparotomy which revealed a ileal stricture, a few centimeters away from

ileocecal valve, surrounded by a conglomerate of multiple intestinal loops.

Terminal ileus was resected and intestinal continuity was restored through a primary manual ileocecal anastomosis. The patient made an uncomplicated recovery and was discharged 9 days later. Histological examination (Figure 3) revealed a poorly differentiated adenocarcinoma, extending through the bowel wall and invading muscle and sierosa. Remaining ileum was characterised by surface irregularity, transmural inflammation, glandular distortion and atrophy, cryptitis, non-necrotizing granulomas and metaplasia as active Crohn's disease. Three of 11 lymph nodes examined were metastatic. Immunohistochemistry of the tumor cells was positive for CK19 and CK20 and negative for CK7, chromogranin and synaptophysin.

Discussion

It has been proven that the risk of SBA rises significantly (3, 4) in Crohn's disease and some authors suggest it is increased more than 60-fold (7) as compared to the general population. Cancer affects the ileum twice as commonly as the jejunum and four times as commonly as the duodenum. The most frequent histotype is adenocarcinoma and its risk factors

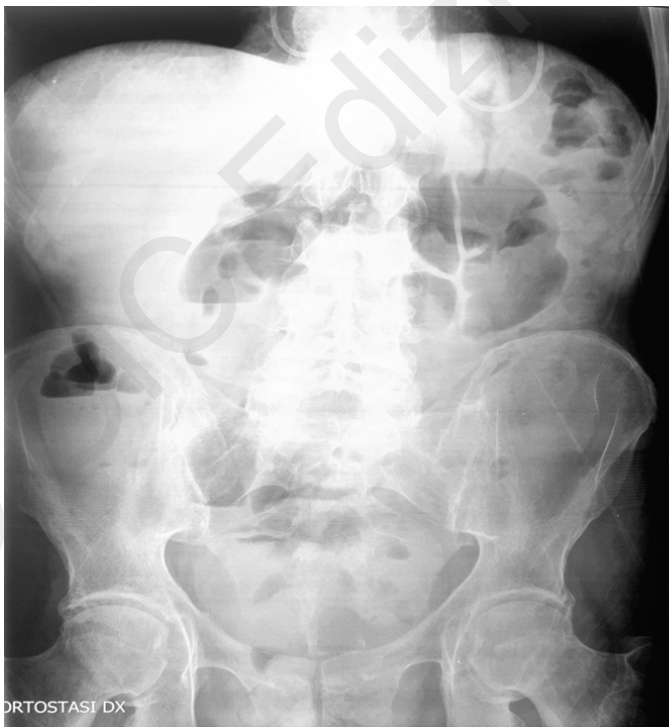

Figure 1 - Abdominal plain film X-rays with intestinal obstruction.

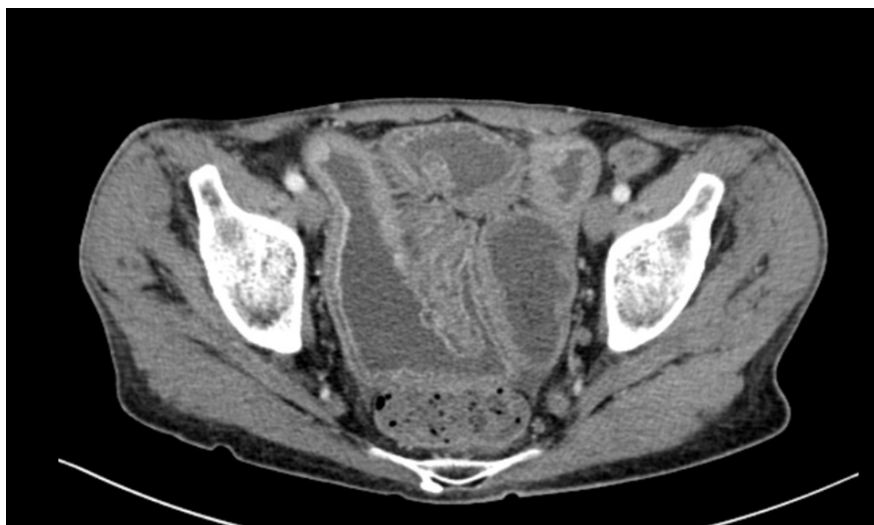

Figure 2 - CT with dilatation of small bowel loops and wall thickening of terminal ileus.

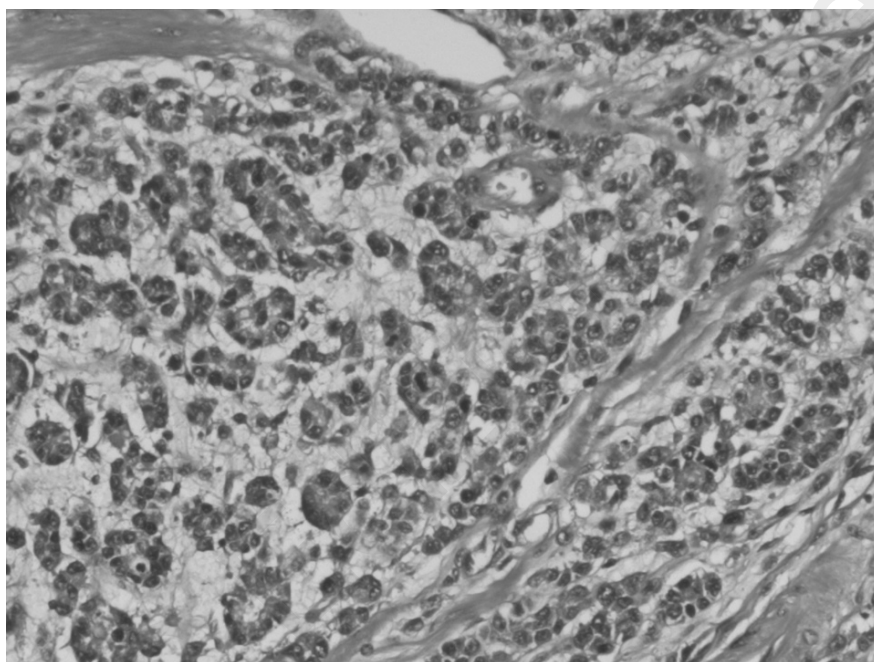


Figure 3 - Primary mucinous adenocarcinoma of the ileum complicating Crohn disease.

include long-standing and extensive Crohn's disease, young age, male sex, smoke, early onset, complications such as strictures and fistulas (8). The role of surgically bypassed loops is controversial. Hazardous occupations and proximal disease localization may be associated with an higher risk (9) as CD restricted only to the small bowel versus ileocolic inflammation (10). Endoscopic surveillance is crucial to decrease risk of neoplasia by detecting pre-neoplastic lesions but stricturing CD may lead to incomplete surveillance, especially when multiple stenoses are present (11).

The correlation between monoclonal tumor necro-

sis factor alpha (TNF- α) antibodies, immunosuppressive antimetabolites and their impact on carcinogenesis is still under debate. TNF- α initiates cellular apoptosis of malignant cells but it is also secreted by tumors to enhance neoplastic proliferation as a pro-tumorigenic inflammatory cytokine (12,13). Thiopurines and methotrexate may damage DNA, activate oncogenes and reduce physiologic immunosurveillance, promoting cancer development (14,15). A recent retrospective study that included 333 patients with IBD and history of cancer exposed to anti-TNF and/or antimetabolites had showed they are not as-

sociated with an increased risk of cancer in this cohort(16). Conversely, several studies (3,6,17) have established 5-ASAs prevent the development of intestinal adenocarcinoma in IBD. According to these reports, it is interesting to raise the question whether the patient was not treated with aminosalicylate for years and had a lot of risk factors such as male gender, “young” age, smoke, long-standing ileal disease and likely preceding strictures.

The most common clinical presentation of small bowel carcinoma in Crohn’s disease is quite similar to its acute exacerbation. The patient presents intestinal obstruction with nausea, vomit and abdominal pain, accompanied by previous weight loss such as in our case report. Hemorrhage, fistula or perforation are less frequent. Therefore, these malignancies were indistinguishable radiologically from longstanding Crohn’s disease because imaging techniques may not be able to differentiate areas of small bowel carcinomas from benign fibrotic or acute inflammatory strictures (8). The diagnosis is very challenging and only 5% of SBA is detected preoperatively, while the greater part is discovered incidentally during pathologic examination of resected specimens (18).

The treatment of choice is wide resection of small bowel segment and the resection of corresponding mesentery and lymph node (18). To date, no standard adjuvant regimen has been defined due to the lack of

randomised controlled trials. The only data available are those from retrospective studies (19) that have found no benefit in adjuvant chemotherapy after potentially curative surgical resections of SBA. In patients with a high risk of recurrence (defined as a lymph node ratio (invaded/without metastasis) $\geq 10\%$), adjuvant therapy appeared to improve OS (20). Small bowel carcinomas associated with Crohn’s disease tends to be poorly differentiated and are associated with a poor prognosis with a mean survival of 6 mo. Poor prognostic factors include positive resection margins, extramural venous spread, lymph node metastases, poor tumor differentiation, depth of tumor, and a history of Crohn’s disease. Two year survival rates have been found to be as low as 27%. Mortality rates range from 30%-60% depending on the stage of the carcinoma (21, 22).

Conclusion

Small bowel adenocarcinoma is a rare disease but it must be considered in patients with strictures for Crohn’s disease. Preoperative diagnosis is still highly challenging despite significant radiological and endoscopic progress. Medical drugs as 5-ASA may have a preventive role and it might be life-threatening do not administer these to potentially high risk patients.

References

1. Ginzburg L, Schneider L, Dreizin D, Levinson C. Carcinoma of the jejunum occurring in a case of regional enteritis. *Surgery*. 1956 Feb;39(2):347-51.
2. Faivre J, Trama A, De Angelis R, et al. Incidence, prevalence and survival of patients with rare epithelial digestive cancers diagnosed in Europe in 1995-2002. *European Journal of Cancer*. 2012;48:1417-24.
3. Bernstein CN, Blanchard JF, Kliever E, et al. Cancer risk in patients with inflammatory bowel disease: a population-based study. *Cancer*. 2001;91:854-862.
4. Jess T, Loftus EV Jr, Velayos FS, et al. Risk of intestinal cancer in inflammatory bowel disease: a population-based study from Olmsted county, Minnesota. *Gastroenterology*. 2006;130:1039-1046.
5. Palascak-Juif V, Bouvier AM, Cosnes J, et al. Small bowel adenocarcinoma in patients with Crohn’s disease compared with small bowel adenocarcinoma de novo. *Inflammatory Bowel Diseases*. 2005;11:828-832.
6. Piton G, Cosnes J, Monnet E, et al. Risk factors associated with small bowel adenocarcinoma in Crohn’s disease: a case-control study. *The American Journal of Gastroenterology*. 2008;103:1730-1736.
7. Jess T, Winther KV, Munkholm P, Langholz E, Binder V. Alimenter Pharmacol Ther. Intestinal and extra-intestinal cancer in Crohn’s disease: follow-up of a population-based cohort in Copenhagen County, Denmark. 2004 Feb 1;19(3):287-93.
8. Cahill C, Gordon PH, Petrucci A, Boutros M. Small bowel adenocarcinoma and Crohn’s disease: Any further ahead than 50 years ago? *World J Gastroenterol*. 2014 Sep 7;20(33):11486-11495.
9. Lashner BA. Risk factor for small bowel cancer in Chron’s disease. *Dig Dis Sci*. 1992 Aug;37(8):1179-84.
10. von Roon AC, Reese G, Teare J, Constantinides V, Darzi AW, Tekkis PP. The risk of cancer in patients with Crohn’s disease. *Dis Colon Rectum*. 2007;50:839-855.
11. Kristo I, Riss S, Argeny S, Maschke S, Chitsabesan P, Stift A. Incidental adenocarcinoma in patients undergoing surgery for stricturing Crohn’s disease. *World J Gastroenterol*. Jan 21, 2017;23(3):472-477.
12. Beaugerie L. Inflammatory bowel disease therapies and cancer risk: where are we and where are we going? *Gut*. 2012;61:476-483.
13. Balkwill F. Tumour necrosis factor and cancer. *Nat Rev Cancer*. 2009;9:361-371.
14. O’Donovan P, Perrett CM, Zhang X, Montaner B, Xu YZ, Harwood CA, McGregor JM, Walker SL, Hanaoka F, Karran P. Azathioprine and UVA light generate mutagenic oxidative DNA damage. *Science*. 2005;309:1871-1874.
15. Zitvogel L, Tesniere A, Kroemer G. Cancer despite immunosurveillance: immunoselection and immunosubversion. *Nat Rev Immunol*. 2006;6:715-727.

16. Axelrad J, Bernheim O, Colombel JF, Malerba S, Ananthakrishnan A, Yajnik V, Hoffman G, Agrawal M, Lukin D, Desai A. Risk of New or Recurrent Cancer in Patients With Inflammatory Bowel Disease and Previous Cancer Exposed to Immunosuppressive and Anti-Tumor Necrosis Factor Agents. *Clin Gastroenterol Hepatol*. 2016;14:58-64.
 17. Solem CA, Harmsen WS, Zinsmeister AR, Loftus EV Jr. Small intestinal adenocarcinoma in Crohn's disease: a case-control study. *In amm Bowel Dis*. 2004;10:32-35.
 18. Dossett LA, White LM, Welch DC, Herline AJ, Muldoon RL, Schwartz DA, Wise PE. Small bowel adenocarcinoma complicating Crohn's disease: case series and review of the literature. *Am Surg*. 2007;73:1181-1187.
 19. Aparicio T, et al. Small bowel adenocarcinoma: Epidemiology, risk factors, diagnosis and treatment. *Digestive and Liver Disease*. 2014;46(2):97-104.
 20. Overman MJ, Kopetz S, Lin E, et al. Is there a role for adjuvant therapy in resected adenocarcinoma of the small intestine. *Acta Oncologica*. 2010;49:474-9.
 21. Reddy VB, Aslanian H, Suh N, Longo WE. Asymptomatic ileal adenocarcinoma in the setting of undiagnosed Crohn's disease. *World J Gastroenterol*. 2008 Aug 7;14(29):4690-4693.
 22. Maitines G, Ugenti I, Memeo R, Clemente N, Iambrenghi OC. Endoscopic gastrostomy for enteral nutrition in neurogenic dysphagia: Application of a nasogastric tube or percutaneous endoscopic gastrostomy. *Chir Ital*. 2009 Jan-Feb;61(1):33-8.
-