

See discussions, stats, and author profiles for this publication at: <https://www.researchgate.net/publication/322040607>

Total laparoscopic splenectomy for giant epidermoid cyst: a case report

Article in *Il Giornale di Chirurgia - Journal of Surgery* · July 2017

CITATIONS

3

READS

353

9 authors, including:



Giuseppe Carbotta

Policlinico di Bari

27 PUBLICATIONS 197 CITATIONS

[SEE PROFILE](#)



Salvatore Fedele

Policlinico di Bari

20 PUBLICATIONS 87 CITATIONS

[SEE PROFILE](#)



Antonella Delvecchio

Ospedale Generale Regionale "F. Miulli"

50 PUBLICATIONS 390 CITATIONS

[SEE PROFILE](#)

Total laparoscopic splenectomy for giant epidermoid cyst: a case report

P. LOBASCIO, G. CARBOTTA, R. LAFORGIA, S. FEDELE, M.G. SEDERINO,
M. MINAFRA, A. DELVECCHIO, F. FERRARESE, N. PALASCIANO

SUMMARY: Total laparoscopic splenectomy for giant epidermoid cyst: a case report.

P. LOBASCIO, G. CARBOTTA, R. LAFORGIA, S. FEDELE, M.G. SEDERINO,
M. MINAFRA, A. DELVECCHIO, F. FERRARESE, N. PALASCIANO

Introduction. Splenic cysts are benign tumors, accidentally detected using US or CT scan. They are classified into true cyst (primary, 25%) and pseudocyst (secondary, 75%). Conventional treatment of splenic cyst, especially giant, symptomatic and complicated has been open or laparoscopic total splenectomy. Recently, partial splenectomy is recommended as well to preserve its hematopoietic function and homeostasis of blood, but it is not considered safe for complications as intra and post operative bleeding.

Case report. A 46 years old man, martial arts practitioner, underwent US abdomen scan because of left upper quadrant pain, with evidence of a splenic mass. He underwent also CT and MRI, which revealed "oval giant splenic mass of 12 cm diameter located in superior splenic pole that can be firstly referred to cyst". Considered patient's frequency to thoraco-abdominal traumas, we decided to perform a total laparoscopic splenectomy. Surgical treatment was performed with a three trocar technique and lasted 150 minutes. Post-operative follow-up was regular and abdominal drain was removed in 4th POD (Post Operative Day). Patient was discharged in 5th POD. Pathological examination revealed epidermoid cyst.

Conclusions. Total splenectomy needs to be performed in cases of giant cyst and in our limited experience it is a safe approach.

KEY WORDS: Epidermoid splenic cyst - Laparoscopy - Splenectomy.

Introduction

Giant epidermoid splenic cysts are rare benign tumors. They are classified into true cyst (primary, 25%) and pseudocyst (secondary, 75%), according to the presence of an epithelial cellular lining inside the cyst (1). True cysts are subdivided into parasitic (caused by *Echinococcus* G.) and non-parasitic. Non parasitic can be either divided into congenital or neoplastic tumors. Congenital cysts can be differentiated in epidermoid, dermoid and endodermoid (2). Splenic epidermoid cyst represents approximately 10% of total cysts and is more commonly in female and in less than 40 years old patients. Normally, they are asymptomatic but sometimes a dull pain can be felt in left upper quadrant.

During last 15 years, splenic cysts are detected

more frequently because of the development of modern technology (3).

Splenic cysts could be treated surgically according to specific criteria as size, number, location, relation to hilus, patient's age. Tailored surgical procedure needs to be performed on specific cases in order to avoid dangerous complications such as spleen rupture or cyst infection with abscess (4). Laparoscopic technique has now become the standard surgical approach, especially spleen preserving minimally invasive procedures. Indeed partial splenectomy (PS) is increasingly being promoted (5) to preserve at least 25% of splenic parenchyma and it is based on splenic vascular anatomy (6). PS is useful to avoid the risk of thrombocytosis and postoperative infections. Unfortunately, PS compared to total splenectomy (TS) is still a great challenge because it's crucial to ensure an adequate hemostasis, indeed the use of the technique is currently limited (7).

Case report

A 46 years old man, martial arts practitioner, underwent US abdomen scan because of orchiopididymi-

General Surgery Unit "V. Bonomo", Department of Emergency and Transplantation of Organs, University of Bari, Bari, Italy

Corresponding author: Pierluigi Lobascio, e-mail: pierloba@hotmail.com;

© Copyright 2017, CIC Edizioni Internazionali, Roma

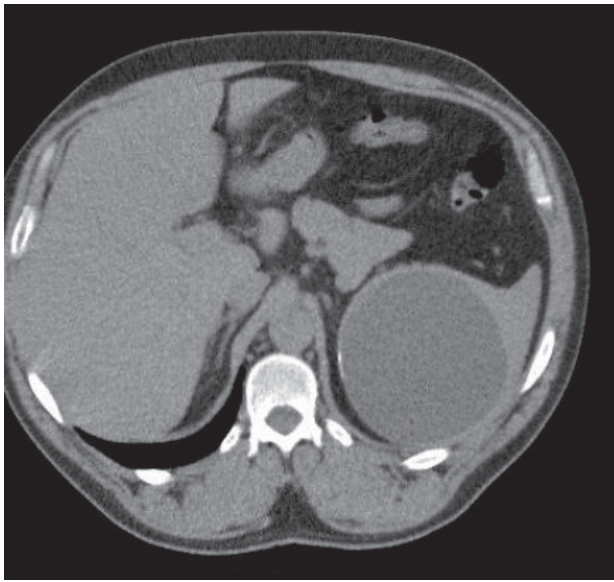


Figure 1 - CT scan of splenic mass.

tis, with incidental evidence of a round hypoechoic cystic mass of the upper pole of the spleen with regular thin wall. He underwent also CT scan and MRI, which revealed “oval giant splenic mass of 12 cm diameter located in superior splenic pole that can be firstly referred to cyst” (Figures 1, 2). Considered patient’s frequency to thoraco-abdominal traumas, we decided to perform a total laparoscopic splenectomy.

Before surgical procedure, intravenous Cefazolin was administered and thereafter every 12 hours associated to analgesics as Paracetamol and Tramadol. Surgical procedure was performed with a three trocar technique: 20° anti Trendelenburg modified lithotomy and on 45° right lateral side. 1st trocar was inserted in a standard umbilical position using Hasson’s open technique to create pneumoperitoneum; 2nd trocar, 12-mm port, was inserted in the right midclavicular line 3 cm below the costal margin according to the size of the spleen; 3rd trocar, 12-mm port, was inserted on the left midaxillary line. Operative time was 150 minutes.

Extraction of specimen was performed *in toto* in bag using a Pfannenstiel incision, as firstly decided after a multidisciplinary meeting with pathologists. Post-operative follow-up was regular and abdominal drain was removed in 4th POD (post operative day). Patient was discharged in 5th POD. Pathological examination revealed epidermoid cyst of the spleen (Figure 3).

Discussion

Laparoscopic procedure for splenic diseases minimizes postoperative pain, encourages early mobilization and

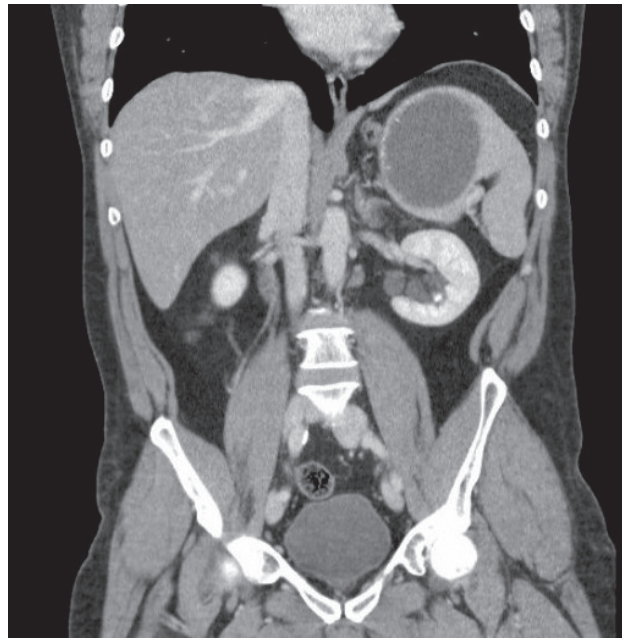


Figure 2 - CT scan of splenic mass.

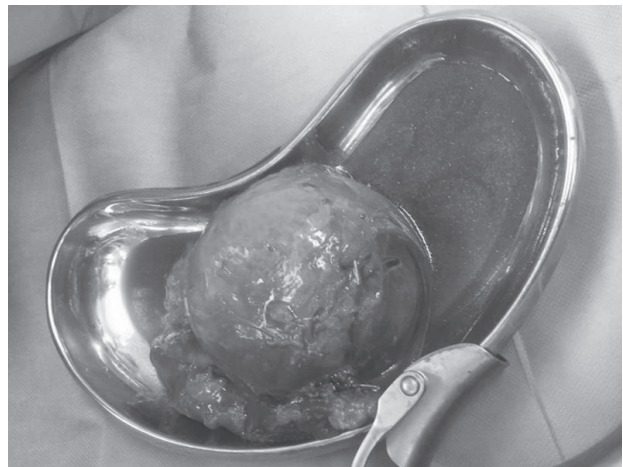


Figure 3 - Epidermoid cyst of the spleen.

return to normal daily activities. In recent years, spleen-preserving surgery is increasingly being promoted as the leading treatment of non parasitic primary splenic cysts.

Wang (8) et al. reported that PS is technically practical and provides encouraging short- and long-term outcomes for selected patients compared to TS. According to their results, TS showed a higher incidence of thrombocytosis and splenic vein thrombosis. Quesada (7) et al reported a case of a 27years old woman, symptomatic, with a 16,6 cm cyst who underwent a PS using a specific device that provides coagulation and transection and a protective coagulation of the remnant parenchyma.

They described a fluid serous collection as post-operative complication in 9th POD. Golmohammadzadeh (9) et al. considered a case series of 16 symptomatic pts with cysts of a 14 cm mean size, whose 9 TS, 5 PS, and 2 conservative medical treatment. Their results underline that both procedures are appropriate treatments for splenic cysts with low rate of recurrence and complications.

Pitiakoudis (10) et al. described a case of a 19 years old symptomatic female pt, with a 17 cm size cyst, that underwent a PS with decapsulation. In 3rd POD a surgical procedure of TS was needed because of possible postoperative splenic ischemia. In our case we considered both a limited experience and patient's frequency to thoraco-abdominal traumas and we decided to perform a total laparoscopic splenectomy.

In literature, PS versus TS is still a controversial challenge.

Conclusions

Total splenectomy needs to be performed in cases of giant cyst and in our limited experience it is a safe approach.

Laparoscopic procedure shows also economic advantages for reducing post-operative hospital stay, post-operative pain and for a good integrity of abdominal wall. Spleen-preserving surgery must be the leading aim of non parasitic primary splenic cysts especially in University Hospital.

Consent section

Written informed consent was obtained from the patient for publication of this case report and accompanying images.

References

1. Dachman AH, Ros PR, et al. Nonparasitic splenic cysts : a report of 52 cases with radiologic-pathologic correlation. *AJRAm J Roentgenol.* 1986;147:537-42.
2. Karfis EA, Roustanis E, Tsimoyannis EC. Surgical management of nonparasitic cysts. *JSLs.* 2009;13:207-12.
3. Valverde Martinez A, Roldan Ortiz S, et al. Partial splenectomy for a giant epidermoid cyst of the spleen., *Clin Case Rep.* 2016;8;4(10):1013-1016.
4. Fernández-López AJ, Candel-Arenas M, et al. Laparoscopic cleavage in splenic symptomatic cyst. *Cir Cir.* 2016.
5. Bong JJ, Kumar R, et al. A novel technique of partial splenectomy using radiofrequency ablation. *J Gastrointest Surgery.* 2011;15(2):371-2.
6. Sayo M, Toshifumi M, et al. Huge splenic epidermoid cyst with elevation of serum Ca19-9 level. *J Med Invest.* 2015;62:89-92.
7. Quesada R, Poves I, Iglesias M. Laparoscopic partial splenectomy for giant cyst using a radiofrequency-assisted device: a case report. *Surg Case Rep.* 2016;2(1):82.
8. Wang L, Zu J, et al. Partial Splenectomy is Superior to Total Splenectomy for Selected Patients with Hemangiomas or Cysts. *World J Surg.* 2017.
9. Golmohammadzadeh H, Maddah G, Shams Hojjati Y, et al. Splenic cysts: Analysis of 16 cases. *Caspian J Intern Med.* 2016;7(3):217-221.
10. Pitiakoudis M, Zazos P, Oikonomou A, et al. Total Splenectomy due to an Unexpected "Complication" after Successful Extended Laparoscopic Partial Decapsulation of a Giant Epidermoid Splenic Cyst: A Case Report. *Case Rep Med.* 2011.